

Riboflavin/Ultraviolet-A–induced Collagen Crosslinking for the Treatment of Keratoconus

GREGOR WOLLENSAK, MD, EBERHARD SPOERL, PhD, AND THEO SEILER, PhD, MD

• **PURPOSE:** In animal eyes, a significant increase in corneal biomechanical stiffness has been found after collagen crosslinking by combined riboflavin/ultraviolet-A (UVA) treatment. The aim of the present study was to evaluate the clinical usefulness of riboflavin/UVA-induced collagen crosslinking for bringing the progression of keratoconus to a halt.

• **DESIGN:** Prospective, nonrandomized clinical pilot study.

• **METHODS:** Twenty-three eyes of 22 patients with moderate or advanced progressive keratoconus (maximum K value, 48–72 diopters) were included. After central corneal abrasion, photosensitizing riboflavin drops were applied and the eyes exposed to UVA (370 nm, 3 mW/cm²) in a 1-cm distance for 30 minutes. Postoperative examinations were performed in 6-month intervals, including visual acuity testing, corneal topography, slit-lamp examination, measurement of endothelial cell density, and photographic documentation. The follow-up time was between 3 months and 4 years.

• **RESULTS:** In all treated eyes, the progression of keratoconus was at least stopped. In 16 eyes (70%) regression with a reduction of the maximal keratometry readings by 2.01 diopters and of the refractive error by 1.14 diopters was found. Corneal and lens transparency, endothelial cell density, and intraocular pressure remained unchanged. Visual acuity improved slightly in 15 eyes (65%).

• **CONCLUSIONS:** Collagen crosslinking may be a new way for stopping the progression of keratectasia in patients with keratoconus. The need for penetrating keratoplasty might then be significantly reduced in keratoconus. Given the simplicity and minimal costs of the treatment, it might also be well-suited for developing countries. Long-term results are necessary to evaluate the duration of the stiffening effect and to exclude long

term side-effects. (*Am J Ophthalmol* 2003;135:620–627. © 2003 by Elsevier Inc. All rights reserved.)

KERATOCONUS IS A NONINFLAMMATORY CONELIKE ectasia of the cornea, which is usually bilateral and progresses over time. Its reported frequency is approximately 1 in 2,000 in the general population.¹ Usually, the condition starts at puberty, progressing in approximately 20% to such an extent that penetrating keratoplasty becomes necessary.^{2,3}

Besides penetrating keratoplasty, hard contact lenses are the major treatment modality for keratoconus. In rare cases, epikeratoplasty, photorefractive keratectomy, or intracorneal rings can be considered.^{1,4–7} However, all of these techniques only correct the refractive errors of keratoconus but do not treat the cause underlying the corneal ectasia and therefore cannot stop the progression of keratoconus.

A new technique of collagen crosslinking by the photosensitizer riboflavin and UVA similar to photopolymerization in polymers⁸ has been developed. In extensive experimental studies in rabbit and porcine eyes, including biomechanical stress–strain measurements,^{9–11} we showed a significant increase in corneal rigidity by approximately 70% in untreated vs treated corneas⁹ (Figure 1) after collagen crosslinking by the combined riboflavin/UVA treatment.

The aim of the present pilot study was to evaluate the effect of the new crosslinking method on the progression of keratectasia in patients with keratoconus and to exclude possible serious side effects.

DESIGN

THIS WAS A PROSPECTIVE, NON-RANDOMIZED PILOT STUDY.

METHODS

• **SETTING AND PATIENTS:** Starting in 1998, 23 eyes of 22 patients (10 females, 12 males) from the University Eye Clinic of Dresden were included in the study. The clinical

Accepted for publication Dec 2, 2002.

InternetAdvance publication at ajo.com Feb 26, 2002.

From the Department of Ophthalmology, Technical University of Dresden, Dresden, Germany (G.W., E.S), and the Department of Ophthalmology, University of Zurich, Zurich, Switzerland (T.S.).

Inquiries to Gregor Wollensak, MD, University Eye Clinic Dresden, Fetscherstrasse 74, D-01307 Dresden, Germany; fax: (+49) 351-458-4335; e-mail: gwoollens@hotmail.com

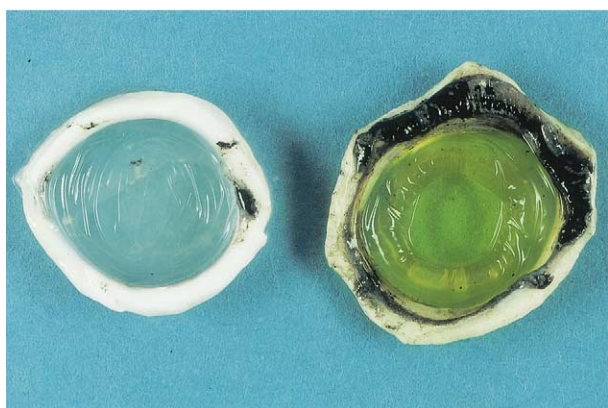
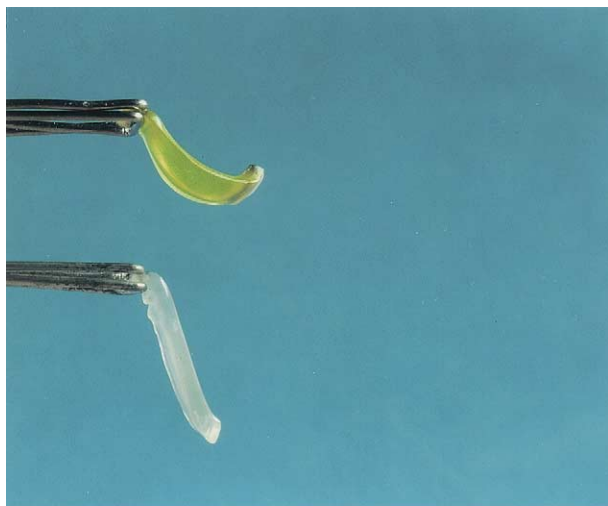


FIGURE 1. (Top) Stiffening effect of porcine cornea after crosslinking with preserved curvature in the treated cornea (above) and massive bending of the untreated control cornea (below). (Bottom) Wrinkling of untreated porcine cornea (left) and form stability with impressive smoothness of the centrally crosslinked porcine cornea (right).

diagnosis of keratoconus was based on corneal topography (Figure 3) and clinical signs of keratoconus such as stromal thinning, Fleischer ring, Vogt striae, or apical stromal scar. The preoperative progression of keratoconus was confirmed from medical history in all patients, and it was clearly documented by serial corneal topography¹² in 12 eyes (52%; Figure 4). The average age of the recruited patients was 31.7 ± 11.9 years and ranged from 13 to 58 years (Tables 1 and 2). Except for patient 1, who had congenital Leber amaurosis and acute bilateral keratoconus, the patients had a moderate to advanced degree of progressive keratoconus¹³ with maximum keratometer values between 48 and 72 diopters (Tables 1 and 2). For safety reasons, in all cases except patient 1, only one eye was treated; the fellow eye served as a control eye. Patients 11 and 22 wore hard contact lenses in the treated eyes before and after the treatment. The prospective, nonrandomized pilot study was conducted in accordance with the princi-

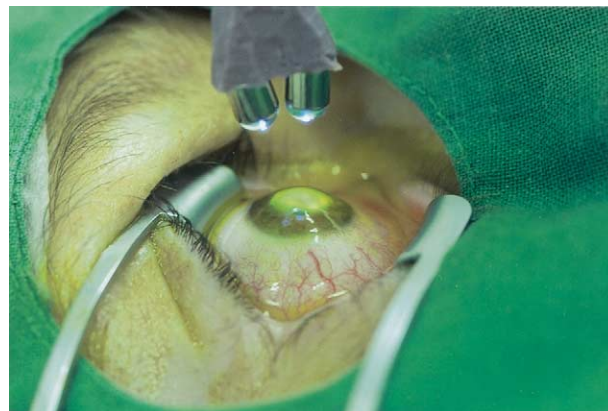

FIGURE 2. Treatment of the central 7 mm of the centrally abraded cornea with riboflavin drops and two UVA diodes.

ples in the Declaration of Helsinki. Subjects read and signed an institutional ethics committee–approved consent form before participation in the study.

• **OBSERVATION PROCEDURES:** The preoperative screening and the postoperative examinations included measurement of best-corrected visual acuity, corneal topography using a videokeratoscope (C-scan; Technomed, Baseweile, Germany), intraocular pressure by Goldmann applanation tonometry, central endothelial cell density using an endothelial cell microscope (EM-1200; Tomey, Erlangen, Germany), corneal photography, and slit-lamp and fundus examination. Preoperative pachymetry (Pachette; Technomed, Baseweile, Germany) was performed only in the last eight patients with minimal pachymetry values ranging from 460 to 540 μm .

• **TREATMENT PROCEDURE:** The treatment procedure was conducted under sterile conditions in the operating room. Proxymetacainhydrochloride 0.5% eyedrops were applied for preoperative local anesthesia. The central 7 mm of the corneal epithelium was cautiously removed using a blunt knife. As a photosensitizer, riboflavin 0.1% solution (10 mg riboflavin-5-phosphate in 10 ml dextran-T-500 20% solution) was applied 5 minutes before the irradiation and every 5 minutes during the irradiation. After allowing riboflavin to permeate through the cornea for at least 5 minutes, the UVA irradiation was started using two UV diodes (370 nm; Roithner Lasertechnik, Vienna, Austria) with a potentiometer in series to regulate the voltage. Three 1.3-V accumulators were used as a power generator. Before each treatment, the desired irradiance of $3 \text{ mW}/\text{cm}^2$ was controlled with a UVA meter (LaserMate-Q; LASER 2000, Wessling, Germany) at a 1-cm distance and, if necessary, regulated with the potentiometer. The patient's cornea was irradiated with the UVA-light diodes (370 nm) at a 1-cm distance for 30 minutes using $3 \text{ mW}/\text{cm}^2$ irradiance, which corresponds to

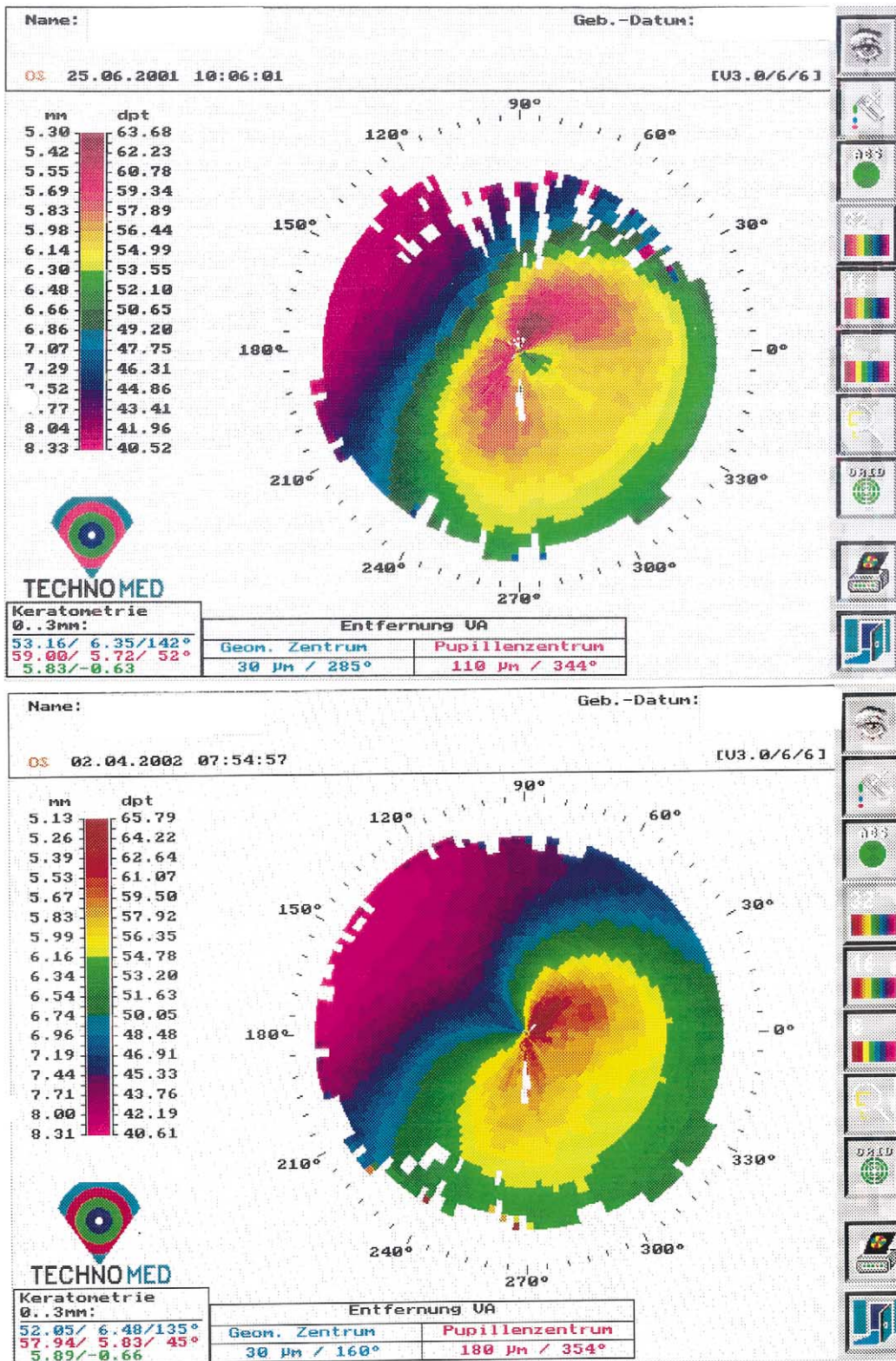


FIGURE 3. Corneal topography of a treated patient (Top) shortly before and (Bottom) 10 months after crosslinking with slight regression of the maximum K value by 1.06 diopters.

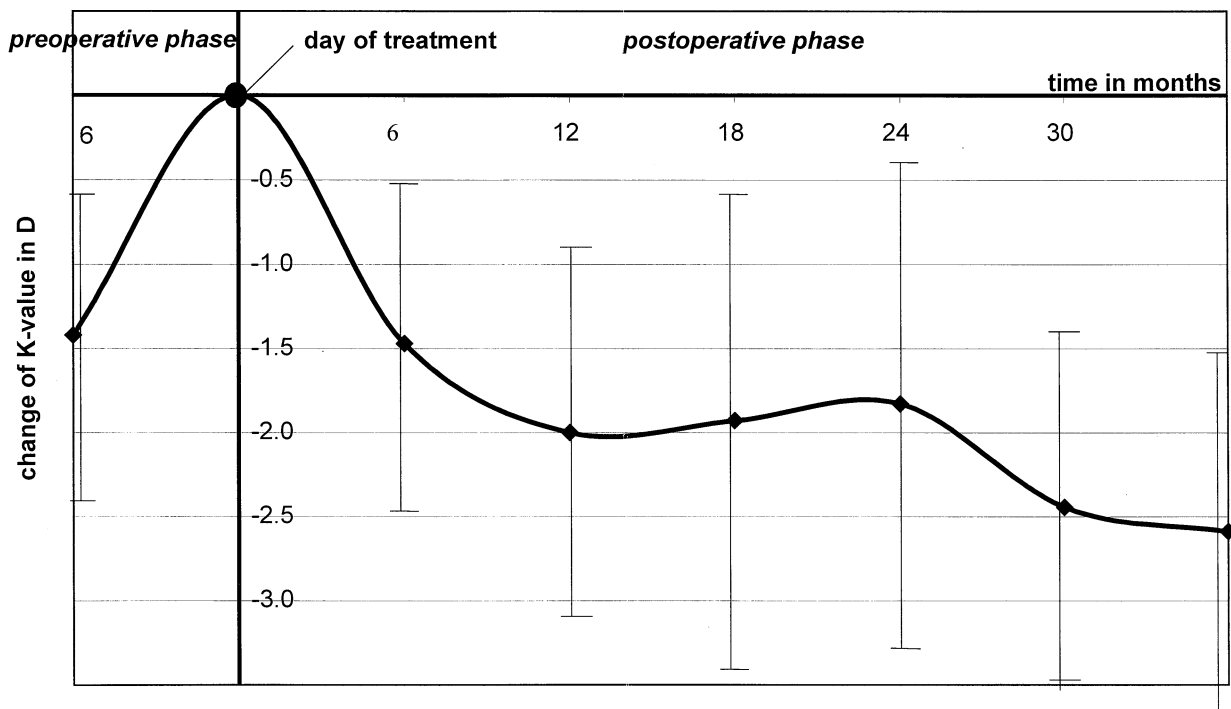
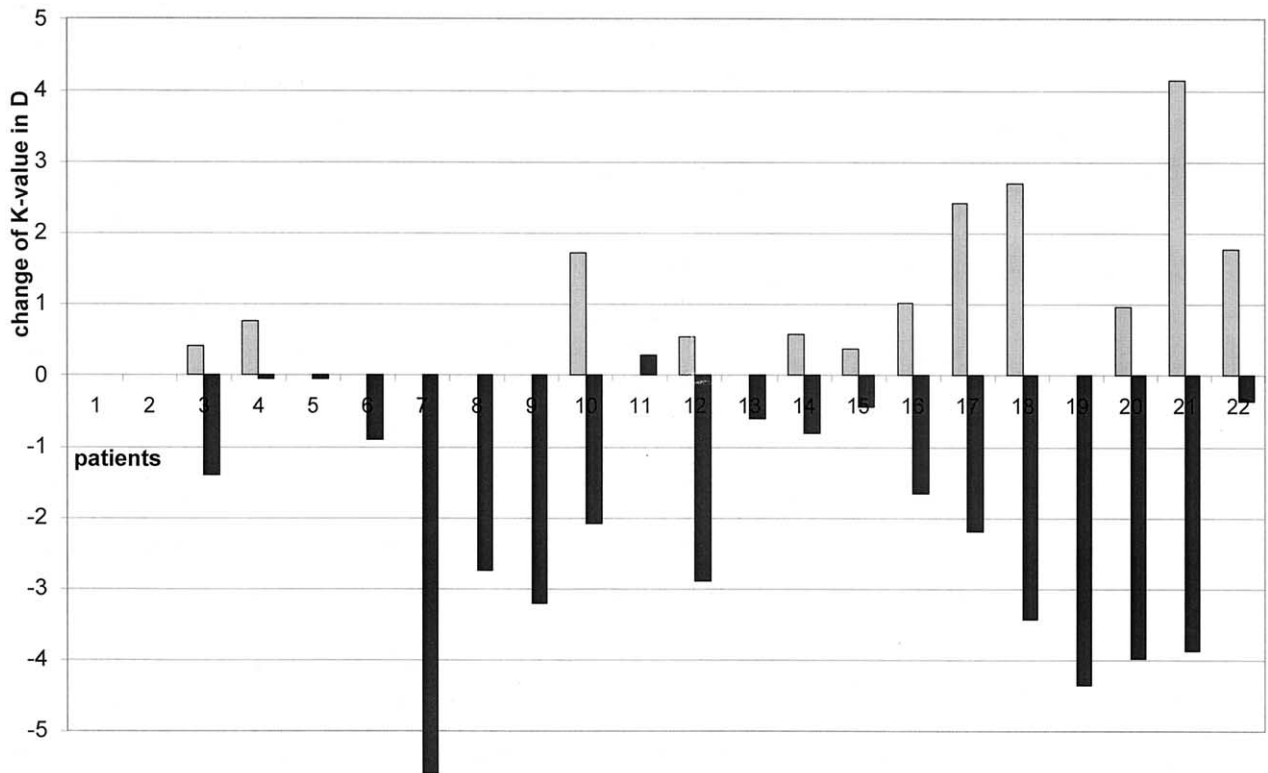


FIGURE 4. (Top) Column diagram demonstrating pretreatment progression of maximum K value in the half year before treatment and posttreatment regression as measured at the latest follow-up examination for each patient. y axis: difference in maximum K value in diopters; x axis: patient number; shaded bars = preoperative change of K value; solid bars = postoperative change of K value. (Bottom) Biphasic curve illustrating the mean change over time of the maximum K value relative to the K value on the day of treatment with mean preoperative progression by 1.4 diopters and postoperative regression by 2.0 diopters (x axis: time in months; y axis: change of maximum K value in D).

TABLE 1. Investigation Parameters

Patient	Age	Postoperative Interval	Visual Acuity		Refractive Correction		Maximum K Value		Endothelial Cell Density		Corneal and Lens Transparency
			Preop	Postop	Preop	Postop	Preop	Postop	Preop	Postop	
1r	13	47	no LP	no LP	—	—	—	—	—	—	=
1l	13	47	no LP	no LP	—	—	—	—	—	—	=
2	41	35	HM	20/400	—	—	—	—	—	—	=
3	32	33	20/50	20/22	-3	-1.5	49.69	48.30	2,300	2,300	=
4	19	33	20/40	20/33	-1.75	-1.5	57.94	57.90	2,400	2,390	=
5	38	31	20/25	20/20	-0.75	-0.75	49.36	49.32	2,200	2,250	=
6	58	31	HM	HM	-3	-2.75	49.10	48.20	1,700	1,700	=
7	49	30	20/25	20/25	3.5	3.5	50.32	44.45	—	—	=
8	36	29	20/33	20/28	-8.25	-3.5	50.94	48.20	2,600	2,640	=
9	29	29	20/66	20/33	-13	-13.125	56.49	53.29	2,580	2,600	=
10	36	27	20/25	20/22	-4.5	-2.125	53.19	51.11	—	2,700	=
11	31	27	20/40	20/33	-6	-7	49.85	50.13	2,150	2,130	=
12	29	24	20/50	20/28	-7	-5.5	55.50	52.61	2,450	2,450	=
13	39	20	20/66	20/40	-3	0	55.17	54.56	2,290	2,280	=
14	39	19	20/50	20/66	-2.75	-2.5	52.80	52.00	2,110	2,090	=
15	31	19	20/40	20/25	-6.75	-2.125	45.88	45.44	2,360	2,400	=
16	19	12	20/100	20/66	-10.25	-4.25	59.00	57.34	2,060	2,100	=
17	28	9	20/66	20/33	-0.75	-4	56.00	53.81	2,400	2,420	=
18	51	8	20/66	20/200	0.375	-0.875	55.60	52.18	2,100	2,050	=
19	32	7	20/66	20/50	-3.5	-2.5	67.07	62.72	2,700	2,700	=
20	30	6	20/33	20/20	-1.0	0.5	51.06	47.08	2,050	2,050	=
21	24	5	20/66	20/50	-3.0	-2.5	72.47	68.60	1,850	1,850	=
22	22	3	20/50	20/40	-1.25	-0.25	46.07	45.70	1,950	1,900	=

The preoperative values for visual acuity and maximum K value were determined on the day of treatment. The postoperative values are given for the last visits.

= indicates unchanged transparency; HM = hand motion; LP = light perception; postop = postoperative; preop = preoperative.

a dose of 5.4 J/cm² (Figure 2). After the treatment, an antibiotic ointment was applied until reepithelialization.

RESULTS

THE FOLLOW-UP TIME RANGED FROM 3 TO 47 MONTHS, with a mean follow-up time of 23.2 ± 12.9 months (Tables 1 and 2). Best-corrected visual acuity improved statistically significantly in 15 patients (65%) by an average of 1.26 lines (95% confidence interval, -0.68 to 2.21; *P* = .026, paired Student *t* test), comparing the preoperative values on the day of treatment vs the postoperative values of the last examination. The refractive correction improved significantly by an average of 1.14 diopters (95% confidence interval, 0.12 to 2.17; *P* = .03) in spherical equivalent (Table 2).

The mean preoperative progression of the maximum K value was 1.42 ± 1.18 diopters (Figure 4, bottom) in 12 eyes (52%). Postoperative regression of keratoconus, as measured by the maximum K values (Table 1), was found in 16 patients (70%; Figure 4, top and bottom) with an average reduction of 2.01 diopters (95% confidence inter-

val, 1.23 to 3.07 diopters; *P* = .001, paired Student *t* test), comparing the preoperative values on the day of treatment vs the postoperative values of the last examination (Figure 3). In five patients the K value remained stable, and in one patient a minimal increase of the K value of 0.28 diopters was present. In the fellow control eyes, however, 5 of 23 eyes (22%) showed a continuous progression of the maximum K value by an average of 1.48 diopters in the first year after the crosslinking treatment of the contralateral eye.

The postoperative healing process was unremarkable, except for slight transient stromal edema until reepithelialization after 3 days. There were no side effects, such as persistent epithelial defects or scarring. During the first postoperative night, some pain medication was administered. The corneal and lens transparency and the endothelial cell density (*P* = .45) remained unchanged (Tables 1 and 2). Contact lens wear for refractive correction in patients 19 and 22 could be continued without tear film stability problems.

No statistically significant difference was found between the mean preoperative intraocular pressure of 13.6 ± 2.0 mm Hg on the day of treatment and the mean postoper-

TABLE 2. Summary of Patient Data and Results

	Mean ± SD	P Value
Mean follow-up	23.2 ± 12.9 months	
Preoperative progression in K value	1.42 ± 1.18 D	
Postoperative regression K value	2.01 ± 1.74 D	.0001
Postoperative regression in refractive error (spherical equivalent)	1.14 ± 2.18 D	.030
Postoperative increase in visual acuity	1.26 ± 1.5 lines	.026
Postoperative intraocular pressure	Unchanged	.612
Postoperative transparency of lens and cornea	Unchanged	
Postoperative density of endothelial cells	Unchanged	.45
Number of patients: 22		
Number of eyes: 23		
Gender: 12 males, 10 females		
Age: 31.7 ± 11.9 years		

The postoperative values were calculated as the difference between the value on the day of treatment and at the last follow-up visit. The preoperative progression K value was calculated as the difference in K value between the value half a year before treatment and the day of treatment.

ative intraocular pressure of 13.8 ± 2.5 mm Hg ($P = .615$) at the last visit.

DISCUSSION

THIS STUDY HAS SHOWN THAT COLLAGEN-CROSSLINKING appears to be effective in stopping the progression of keratoconus quasi “freezing” the cornea. This effect is corroborated by the following data of the study¹: Postoperative regression was observed in 70% of patients with a decrease of the mean keratometer values by 2.01 diopters postoperatively despite documented preoperative progression by 1.42 diopters in 52%.² The postoperative refractive corrections could also be reduced by an average of 1.14 ± 2.18 diopters.³ In the untreated fellow control eyes, a postoperative progression of keratectasia by 1.48 diopters was found in 22%.⁴ In biomechanical measurements of earlier experiments, an increase in biomechanical stability of approximately 70% was measured.⁹

In contrast to other therapeutic measures for treating keratoconus, such as thermal keratoplasty, intracorneal rings, or epikeratoplasty (which basically are only transient refractive corrections),⁴⁻⁷ the new minimal invasive method presented here seems to be the first approach to stop or even reduce the progression of keratoconus. An arrest of keratoconus by contact lenses has been described only in anecdotal reports but has never been confirmed in a systematic study.¹

The success of crosslinking treatment in keratoconus is not surprising, because a significantly reduced tensile strength has been measured biomechanically¹⁴ in keratoconus and a significant increase in corneal rigidity has been measured in porcine and rabbit corneas treated by

riboflavin/UVA using quantitative biomechanical stress-strain measurements.⁹⁻¹¹ The impressive stiffening effect after riboflavin/UVA treatment (Figure 1) is similar to formaldehyde-induced tissue stiffening and fixation in pathologic specimens caused by collagen crosslinking.

Pathohistologically, we were able to demonstrate a significant increase in collagen fiber diameter as the underlying histopathologic correlate.¹⁵ Increased corneal collagen fiber diameters and increased collagen rigidity have also been described in diabetes mellitus and aging, where collagen crosslinking is also increased.¹⁶⁻¹⁸ In these conditions, keratoconus rarely occurs.¹⁹ Increased resistance to pepsin digestion after crosslinking has been found,²⁰ which might be important for keratoconus because a significantly elevated activity of collagenases has been found.^{21,22}

The arrest of the progression of keratoconus in our patients could have been spontaneous as a so-called forme fruste of keratoconus.²³ In epidemiologic studies, however, 21% of patients with keratoconus progress to a state where keratoplasty is required.^{2,3} In all our cases a progression of keratoconus was known before the beginning of the treatment at least by clinical history and clearly documented by corneal topography in 12 eyes (52%; Figure 4, top). Moreover, postoperative regression was observed in 16 eyes (70%) after treatment, and this has never been reported in the natural course of the disease.

In the two cases with hard contact lens wear (patients 11 and 22), the keratometry readings might have been influenced by an orthokeratoplastic effect,²⁴ but these two cases did not show regression. The contact lenses were still tolerated after crosslinking, and their use did not have to be stopped.

In the present study, we treated moderate to advanced keratoconus stages.¹³ If the good results of the new method are corroborated over time, it would be preferable to treat earlier stages of the disease so that a better visual acuity might be preserved. Earlier stages were not included in this study, because the possible risks involved were not yet known.

We did not find an increase of the mean intraocular pressure values postoperatively. Applanation tonometry is not sensitive enough to reflect the increase in corneal rigidity. A slight increase in intraocular pressure measurement might also be masked by the normal slight variability in intraocular pressure.

We have not observed any complications or adverse events of the new method, especially no decrease in endothelial cell density or cataract formation. We have previously measured the amount of irradiation intensity transmitted by the porcine cornea using a UVA photometer. With 3 mW/cm² of UVA irradiance at the surface of the cornea and a riboflavin concentration of 0.1%, there is a massive reduction of the UVA light by 95%, resulting in an irradiance of 0.15 mW/cm² (= an irradiation dose, 0.27 J/cm²) at the endothelial level in a 500- μ m-thick cornea.⁹ Without riboflavin, the UVA light would be reduced in the cornea only by approximately 30%, with approximately 50% UVA absorption in the lens.²⁵

In experiments with rabbit eyes, the cytotoxic threshold irradiance for the endothelial cells after combined riboflavin/UVA treatment is 0.36 mW/cm² (=0.65 J/cm²), which may be reached with a corneal thickness of under 400 μ m using 3 mW/cm² irradiance (=5.4 J/cm²) at the epithelial level.²⁶ Preoperative pachymetry is essential and was included in the last eight patients of the study. The central corneal thickness in keratoconus usually is not reduced to less than 400 μ m.²⁷ If so, however, the cross-linking treatment should be avoided.

The UVA dose of 0.65 J/cm² (0.36 mW/cm²) is far below a cataractogenic level of 70 J/cm².²⁸ In addition, lens damage is usually induced by UVB light in the wavelength range of 290 to 320 nm, which has a higher energy because of a shorter wavelength than UVA.^{28,29}

The durability of the stiffening effect is unknown. Because the collagen turnover in the cornea is estimated to be between 2 to 3 years,^{30,31} a repeat treatment may become necessary in the long run.

Collagen crosslinking could also be useful for the treatment of iatrogenic keratectasia resulting from laser in situ keratomileusis^{32,33} either as prophylaxis or as postoperative treatment. The new treatment can also be used for treating corneal melting lesions or superficial ulcers.³⁴ The residual corneal thickness should be at least 400 μ m to spare the endothelium.

We believe that collagen crosslinking might become a standard treatment for progressive keratoconus. Long-term studies must exclude serious late complications and confirm the durability of the stiffening effect. The new method

might reduce the need for donor material resulting from keratoconus, which represents approximately 16% of all keratoplasty indications.³⁵ Given the very low costs and the simplicity of the new method, it could be applied in developing countries where access to keratoplasty or contact lenses is a problem.

ACKNOWLEDGMENT

The authors thank Prof. Josef Wollensak (Berlin) for continuous support and stimulation in the development of the new method.

REFERENCES

1. Rabinowitz YS. Keratoconus. *Surv Ophthalmol* 1998;42:297-319.
2. Tuft SJ, Moodaley LC, Gregory WM, Davison CR, Buckley RJ. Prognostic factors for the progression of keratoconus. *Ophthalmology* 1994;101:439-447.
3. Kennedy RH, Bourne WM, Dyer JA. A 48-year clinical and epidemiologic study of keratoconus. *Am J Ophthalmol* 1986;101:267-273.
4. Sekundo W, Stevens JD. Surgical treatment of keratoconus at the turn of the 20th century. *J Refract Surg* 2001;17:69-73.
5. Colin J, Cochener B, Savary G, Malet F. Correcting keratoconus with intracorneal rings. *J Cataract Refract Surg* 2000;26:1117-1122.
6. Dana MR, Putz JL, Viana MAG, Sugar J, McMahon TT. Contact lens failure in keratoconus management. *Ophthalmology* 1992;99:1187-1192.
7. Jaeger MJ, Berson P, Kaufman HE, Green WR. Epikeratoplasty for keratoconus. A clinicopathologic case report. *Cornea* 1987;6:131-139.
8. Hettlich HJ, Lucke K, Kreiner CF. Light induced endocapsular polymerization of injectable lens refilling materials. *Ger J Ophthalmol* 1992;1:346-349.
9. Spoerl E, Schreiber J, Hellmund K, Seiler T, Knuschke P. Untersuchungen zur Verfestigung der Hornhaut am Kaninchen. *Ophthalmologie* 2000;97:203-206.
10. Spoerl E, Huhle M, Seiler T. Induction of cross-links in corneal tissue. *Exp Eye Res* 1998;66:97-103.
11. Spoerl E, Huhle M, Seiler T. Erhöhung der Festigkeit der Hornhaut durch Vernetzung. *Ophthalmologie* 1997;94:902-906.
12. Maguire LJ, Lowry JC. Identifying progression of subclinical keratoconus by serial topography analysis. *Am J Ophthalmol* 1991;112:41-45.
13. Zadnik K, Barr JT, Gordon MO, Edrington TB. Biomicroscopic signs and disease severity in keratoconus. *Cornea* 1996;15:139-146.
14. Andreassen TT, Simonsen AH, Oxlund H. Biomechanical properties of keratoconus and normal corneas. *Exp Eye Res* 1980;31:435-441.
15. Wollensak G, Seiler T, Wilsch M, Spörl E. Collagen fiber diameter after riboflavin/UVA induced collagen-crosslinking in the rabbit cornea. *Cornea*. Forthcoming.
16. Malik NS, Moss SJ, Ahmed N, Furth AJ, Wall RS, Meek KM. Ageing of the human corneal stroma: structural and biochemical changes. *Biochim Biophys Acta* 1992;1138:222-228.
17. Sady C, Khosrot S, Nagaraj R. Advanced Maillard reaction

- and crosslinking of corneal collagen in diabetes. *Biochem Biophys Res Com* 1995;214:793–797.
18. Bailey AJ, Paul RG, Knott L. Mechanisms of maturation and ageing of collagen. *Mech Ageing Dev* 1998;106:1–56.
 19. Seiler T, Huhle S, Spoerl E, Kunath H. Manifest diabetes and keratoconus: a retrospective case-control study. *Graefes Arch Clin Exp Ophthalmol* 2000;238:822–825.
 20. Spoerl E, Seiler T, Wollensak G. Increased resistance of crosslinked cornea against enzymatic digestion. *Br J Ophthalmol*, forthcoming.
 21. Abalain J. Levels of collagen degradation products (telopeptides) in the tear film of patients with keratoconus. *Cornea* 2000;19:474–476.
 22. Zhou L, Sawaguchi S, Twining SS, Sugar J, Feder RS, Yue BY. Expression of degradative enzymes and protease inhibitors in corneas with keratoconus. *Invest Ophthalmol Vis Sci* 1998;39:1117–1124.
 23. Amsler M. Le k eratoc one fruste au Javal. *Ophthalmologica* 1938;96:77–83.
 24. Swarbrick HA, Wong G, O'Leary DJ. Corneal response to orthokeratology. *Optom Vis Sci* 1998;75:791–799.
 25. Michael R. Development and repair of cataract induced by ultraviolet radiation. *Ophthalmic Res* 2000;32(S1):1–44.
 26. Wollensak G, Spoerl E, Seiler T, Wilsch M. Endothelial cell damage after riboflavin-UVA treatment in the rabbit. *J Cataract Refract Surg*, forthcoming.
 27. Watters G, Owens H. Evaluation of mild, moderate, and advanced keratoconus using ultrasound pachymetry and the EyeSys videokeratoscope. *Optom Vis Sci* 1998;75:640–646.
 28. Pitts DG, Cullen AP, Hacker PD. Ocular effects of ultraviolet radiation from 295–365 nm. *Invest Ophthalmol Vis Sci* 1977;16:932–939.
 29. Jose JG, Pitts DG. Wavelength dependency of cataracts in albino mice following chronic exposure. *Exp Eye Res* 1985;41:545–563.
 30. Smelser GK, Polack FM, Ozanics V. Persistence of donor collagen in corneal transplants. *Exp Eye Res* 1965;4:349–354.
 31. Nishida T. Basic Science: Cornea. In: Krachmer JH, Mannis MJ, Holland EJ, editors. *Cornea*, vol. 1. St. Louis: Mosby, 1997:13.
 32. Seiler T, Koufala K, Richter G. Iatrogenic keratectasia after laser in situ keratomileusis. *J Refract Surg* 1998;14:312–317.
 33. Argento C, Cosentino MJ, Tytiun A, Rapetti G, Zarate J. Corneal ectasia after laser in situ keratomileusis. *J Cataract Refract Surg* 2001;27:1440–1448.
 34. Schnitzler E, Sp rl E, Seiler Th. Bestrahlung der Hornhaut mit UV-Licht und Riboflavingabe als neuer Behandlungsversuch bei einschmelzenden Hornhautprozessen, erste Ergebnisse mit Patienten. *Klin Mbl Augenheilk* 2000;217:190–193.
 35. Maeno A, Naor J, Hunter WS, Rootman DS. Three decades of corneal transplantation: indications and patient characteristics. *Cornea* 2000;19:7–11.