

Herpes Zoster Ophthalmicus: More than Meets the Eye

Guillermo Rocha, MD, FRCSC; Mercedes Muzychuk, OD

ABSTRACT

In this paper, a review of the basics of the herpes zoster virus will be covered. Aspects of ophthalmic complications and postherpetic neuralgia will be discussed. Finally, the recent advent of the zoster vaccine will be discussed.

INTRODUCTION

The varicella zoster virus (VZV) causes two distinct clinical manifestations: varicella (chickenpox) and zoster (shingles).¹ After primary infection with VZV (chickenpox), the virus becomes latent in the sensory ganglia.² Herpes zoster occurs when the virus reactivates from the sensory ganglia and spreads to the corresponding dermatome,² producing the characteristic zoster rash. It is thought that the likelihood of reactivation increases with age because of an age-related decrease in cell mediated immunity to the VZV.³ Multiple subclinical reactivations can occur during a lifetime.^{4,5} If reactivation occurs, the re-exposure to VZV is thought to endogenously boost the immunity,⁵ decreasing the chance of further episodes.

During reactivation, VZV replication causes vesicular eruptions and inflammation of the skin producing the characteristic dermatomal zoster rash.⁴ Diagnosis of VZV is supported by the presence of prodromal pain, an asymmetric dermatomal rash respecting the midline, and corresponding zoster-associated segmental pain.⁴ While zoster can occur in any dermatome, it most commonly occurs in the thoracic dermatomes (50% to 56%) and in cranial nerves V, VII, and VIII (20%).⁴ The cervical, lumbar, and sacral segments are less frequently involved.⁴ In its disseminated form, VZV can also involve internal organs.⁴

G. Rocha — Brandon Regional Health Centre, University of Manitoba, Brandon, MB; University of Ottawa Eye Institute, Ottawa, ON; M. Muzychuk — University of Waterloo School of Optometry, Waterloo, ON
Correspondence to: Guillermo Rocha, MD, FRCSC, GRMC Vision Centre, Medical Centre Building, Suite 20, 144-6th Street, Brandon, MB, Canada R7A 3N2; rochag@westman.wave.ca

Dr. Rocha has received consulting fees from Merck Frosst Canada. Dr. Muzychuk has no financial interest in the above-named technology or its applications.

The varicella virus is common; in recent decades the infection was found to affect 50% of Canadians by age 5 and 90% by age 12.⁶ Although the rate of infection with VZV is high, the reported incidence of herpes zoster ranges from 2.2-3.4/1000 people per year.² Incidence and severity increase with age.

Along with variation of incidence with age, there appears to be a disparity between males and females. In a study examining the epidemiology of shingles in Alberta from 1986-2002, the rate of herpes zoster was found to be increasing, with more females being affected than males at every age group, with the disparity between females and males being highest in the 50 to 54 year age group.⁷

The incidence of herpes zoster is also higher in immunocompromised individuals.⁴ Most immunocompromised individuals present with distinct inflammation, hemorrhages, and necrosis that follows a multi-dermatomal pattern.⁴ The rash can also be moderate with few symptoms.⁴ In addition, there is a higher incidence of disseminated zoster among immunocompromised individuals.⁴

HERPES ZOSTER OPHTHALMICUS

Herpes zoster ophthalmicus (HZO) is a manifestation of the varicella zoster virus involving ocular structures. HZO results from reactivation of the VZV in the first (ophthalmic) branch of the trigeminal nerve.⁸ Clinical manifestations (Table I) of HZO can be caused by direct viral invasion, secondary inflammation and changes to the autoimmune mechanisms, and neurotrophic disorders.⁸ If left untreated, 50% to 70% of HZO patients will develop ocular complications⁸ that can threaten the

Table I Clinical manifestations of HZO.⁸

Mechanism ⁸	
Direct viral invasion	Superficial keratitis (punctate keratitis, dendritic keratitis and conjunctivitis)
Secondary inflammation/ Alterations of autoimmune mechanisms	Stromal keratitis Uveitis Scleritis Episcleritis
Neurotrophic changes	Neurotrophic keratitis

Table II Ophthalmic manifestations of HZO. ²		
Structure Involved	Acute Phase	Late Phase
Eyelids	Swelling, vesicular rash	Ptosis, eyelid retraction
Conjunctiva	Conjunctivitis	Self-limiting
Episclera or sclera	Episcleritis Scleritis	Self-limiting Focal sectoral atrophy
Cornea	Epithelial keratitis Stromal keratitis	Neurotrophic or exposure keratopathy Corneal neovascularization, deposition
Anterior chamber	Uveitis* Ocular hypertension	Focal iris atrophy Secondary glaucoma ¹³ Usually self-limiting
Rare complications	Extraocular muscle palsies Optic neuritis Retinal vasculitis, retinitis	Self-limiting, may be related to orbital apex syndrome ¹⁴ Optic atrophy Retinal atrophy

*Unilateral anterior uveitis with sectoral iris atrophy without associated (previous) keratitis is a distinct entity among herpetic eye diseases.¹⁵

long-term integrity and visual function of the eye.⁹ HZO is present in 10% to 20% of all zoster cases.² Approximately 1/100 people will develop HZO in their lifetime.²

Hutchinson's sign, the presence of nasociliary skin lesions, is a useful prognostic factor for ocular inflammation with herpes zoster.⁹ Attention should be focused on the tip of the nose, the inner corner of the eye, and the root and side of the nose to help identify patients at risk of ocular involvement. The nasociliary nerve has two branches: the infratrochlear and external nasal branches, which innervate the skin at the medial canthus of the eye and at the root, and along the side of the nose. This prognostic value of Hutchinson's sign is more significant when both branches of the nasociliary nerve are involved, and there is less likelihood of ocular involvement if lesions are restricted to a single branch.⁹ However, the absence of Hutchinson's sign does not rule out nasociliary nerve involvement. The frontal nerve, which innervates the scalp, forehead, and upper eyelid, is the most common site for the primary and most severe skin lesions in acute ophthalmic zoster.⁹ In patients with acute ophthalmic zoster, the major prognostic factors for ocular inflammation are severity and distribution of skin lesions as this is thought to represent the immune status of the host against the spreading virus.⁹

The prodromal phase begins up to a week before the onset of the skin rash and can involve pain, itching, malaise, photophobia, and low grade fever.² The rash begins with progressive pain sensations and the formation of erythematous macules which then progress to clusters of papules and clear vesicles. New skin lesions typically appear for the next 3 to 5 days; then pustulation and

crusting occur. Although most patients present with the typical HZ rash, a small percentage of patients will present with ophthalmic manifestations alone.²

Ophthalmic Manifestations

Table II describes the ophthalmic manifestations of HZO in both the acute and late phase.²

Eyelids and Ocular Adnexa

Although the varicella rash does not typically result in scarring, cicatricial skin changes often result from HZO. This is more pronounced in the area of the forehead and eyelids because the tissue is thin.¹⁰ If edema of the eyelids is significant, ptosis may result.¹⁰ At the other end of the spectrum, cicatricial changes or orbicularis muscle palsy may result in lagophthalmos.¹⁰ The affected area may also become hypersensitive, making lid manipulation extremely painful (Fig. 1).¹⁰

Conjunctiva

Many different forms of conjunctivitis can result from HZO. These include pseudomembranous, membranous, and follicular responses.¹⁰ A mucopurulent discharge is common during active disease. Vesicles may occur on the bulbar or palpebral conjunctival surfaces. If these vesicles rupture, sequelae range from mild inflammation to infection, ulceration, scarring, and symblepharon formation.¹⁰

Cornea

It is hypothesized that early corneal lesions are due to direct damage from viral invasion while later stages result from vasculitis, immune reactions to viral antigens, delayed hypersensitivity, and/or damage to nerves and

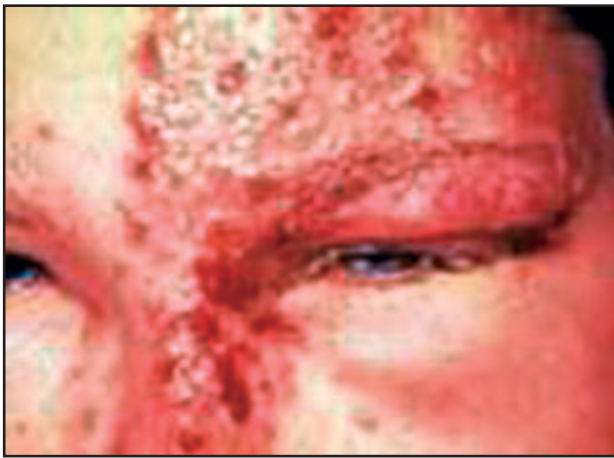

Fig. 1 Herpes zoster ophthalmicus, V1. *Courtesy Michele Mabon, MD, FRCSC.*

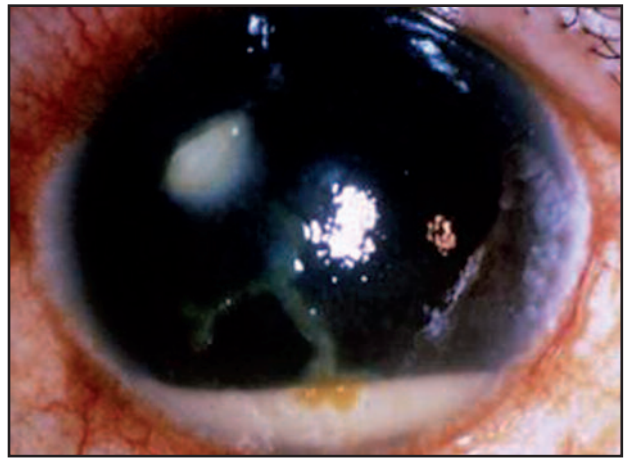


Fig. 2 Corneal pseudodendrite. *Courtesy Michele Mabon, MD, FRCSC.*

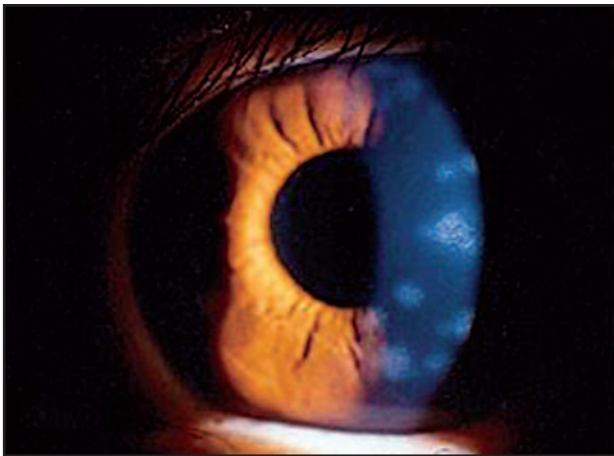


Fig. 3 Nummular keratitis. *Courtesy Michele Mabon, MD, FRCSC.*

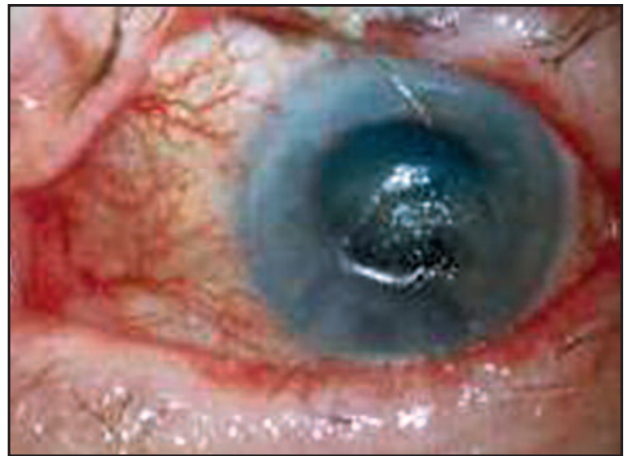

Fig. 4 Neurotrophic keratitis with melt. *Courtesy Michele Mabon, MD, FRCSC.*

tissues.¹⁰ Early corneal findings include punctate epithelial keratitis, pseudodendrites (Fig. 2), and anterior stromal infiltrates (Fig. 3).¹⁰ Later findings include mucous plaques, disciform keratitis, neurotrophic keratitis (Fig. 4), and exposure keratitis.¹⁰ Corneal scarring after infection is common and can range from faint stromal haze to an opaque region with associated thinning.¹⁰ Less commonly, corneal ulcers and perforations can develop.¹⁰

In one case report, a patient with post-zoster corneal scarring was successfully treated with phototherapeutic keratectomy with mitomycin C followed by wavefront-guided photorefractive keratectomy 4 months later.¹¹ In another case report involving a herpes zoster eye in which the patient developed an inflamed hypopyon ulcer which progressed to Descemetocoele, a Boston keratoprosthesis was successfully used to replace the damaged cornea.¹²

In British Columbia from 2001 to 2003, 7.3% of herpes zoster hospitalizations were due to herpes zoster

with ocular manifestations.⁶ It is not known why some develop no HZO complications, or minimal ones, while others develop severe complications.¹⁴ This may be related to virulence of the infection, host immune status, or both.¹⁴

POSTHERPETIC NEURALGIA

Postherpetic neuralgia (PHN), the most common complication of HZ, occurs when pain persists along the course of the nerve after the acute segmental HZ rash has healed.¹⁶ Incidence of PHN is highest at one month after rash resolution and in most patients this pain will improve with time.¹⁶ Depending on the definition, PHN occurs in 9% to 34% of patients,¹⁶ and in at least one-third of these patients the pain cannot be adequately relieved.¹⁶

The incidence and severity of PHN increases with age: at age 60, 50% of patients have pain that persists for longer than one month following the rash, increasing to 75% at age 70.¹⁶ PHN is more commonly encountered

Table III Antiviral drugs that reduce the severity and duration of herpes zoster. ¹⁷		
Antiviral	Dosage	Duration
Acyclovir	800 mg, q4h, 5x/day	7-10 days
Valacyclovir	1000 mg, q8h, 3x/day	7 days
Famciclovir	500 mg, q8h, 3x/day	7 days

in the thoracic dermatomes, especially T5, and in the ophthalmic division of the trigeminal nerve.¹⁶

Considering that 30% to 50% of patients with severe PHN do not respond well (if at all) to treatment, prevention either by vaccination or aggressive treatment of herpes zoster may be the best option.¹⁶

MANAGEMENT

Antiviral drugs (Table III) reduce the severity and duration of herpes zoster but typically do not prevent the development of PHN.¹⁷ If initiated within 72 hours of HZ rash onset, oral antiviral therapy with acyclovir, valacyclovir, and famciclovir decreases the period of acute pain, virus shedding, rash, and both acute and late-onset anterior segment complications.¹⁸ Valacyclovir and famciclovir also decrease the incidence and severity of PHN.¹⁸ In most studies, antiviral therapy is commenced within 72 hours of rash onset but no data exists demonstrating that later antiviral therapy does not provide any therapeutic benefit.¹⁷

It has been demonstrated in clinical trials that acyclovir decreases the pain duration and prevalence of herpes zoster by approximately half.¹⁷ The two newer drugs, valacyclovir and famciclovir, have been shown to have equivalent or superior efficacy in comparison to acyclovir in the treatment of herpes zoster.^{17,19,20} In addition, these two drugs have significantly higher bioavailability¹⁶ and simpler dosing regimens,¹⁷ and they both decrease the incidence and severity of PHN.¹⁸

Antiviral therapy is necessary in patients with HZO in order to prevent or minimize ocular complications. Acyclovir, valacyclovir and famciclovir all have similar efficacy for the treatment of HZO. In a trial with immunocompetent patients with HZO, the incidence and severity of common complications (dendritic keratopathy, stromal keratopathy, uveitis) were significantly decreased with oral acyclovir treatment (600 mg, 5x/day for 10 days) within 7 days of rash onset.¹⁷ In a multicenter, randomized, double-masked study comparing the efficacy and safety of valacyclovir and acyclovir for the treatment of HZO, it was found that valacyclovir (2x 500 mg tablets, 3x/day) is as effective as acyclovir (800 mg, 5x/day) in

preventing ocular complications.⁸ Similarly, another multicenter, randomized, double-masked study found famciclovir (500 mg, 3x/day) to have similar efficacy to acyclovir (800 mg, 5x/day) for HZO.²¹

Acyclovir is available topically in ointment form and may be considered in conjunction with an oral antiviral if eye involvement is severe.² Even though the ointment form creates a much higher concentration of drug in the anterior segment, topical acyclovir is not sufficient for monotherapy.²

Gabapentin can be used in conjunction with antivirals during the acute phase of HZ to help prevent development and minimize severity of postherpetic neuralgia.¹⁷ When pain was assessed after the use of both valacyclovir (1000 mg TID) for 7 days with an increasing dose of gabapentin (maximum dose 1200 mg TID) for 6 months, it was found that at 3 and 6 months post-zoster the reported moderate and severe intensity pain was decreased relative to historic controls treated with acyclovir.¹⁷

Treatment with corticosteroids like prednisolone may be used in conjunction with antivirals to provide initial relief from pain intensity.¹⁷ It has been demonstrated that patients receiving prednisolone had improved cutaneous healing and relief of acute pain.¹⁸ However, this benefit is only experienced during the first few weeks of the disease course and the associated adverse effects may not outweigh the benefits.¹⁷ Corticosteroids have not been found to provide any further decrease in the incidence of PHN when used together with antiviral medications.¹⁷

Current treatment options for PHN include anti-convulsants (gabapentin, pregabalin), lidocaine patch 5%, capsaicin cream, opioid analgesics, and tricyclic antidepressants.¹⁷ In clinical trials, all of these agents are found to alleviate the pain of PHN.¹⁷ Previously, tricyclic antidepressants had been used as the first-line treatment for PHN but gabapentin and the lidocaine patch 5% have superior tolerability and are now both approved as first-line treatments. Opioids can be used for cases that are unresponsive or difficult to manage.¹⁷ Combination therapy is standard in clinical practice.¹⁷

IMPLICATIONS OF CHILDHOOD

VARICELLA VIRUS VACCINATION

Before the varicella vaccination was approved for use in the US in 1995, there was continuing controversy regarding the use of infant varicella vaccination.¹⁴ Considerations included vaccination and revaccination costs, long-term efficacy, whether or not adult varicella would increase as a result, and if this could cause an increase in the incidence of herpes zoster.¹⁴ Some countries have yet to begin vaccination while others have abandoned varicella vaccination programs as a result.¹⁴ A publicly funded varicella vaccination program began in Alberta in 2001 (the vaccine was licensed in Canada in 1998).⁷

Before introduction of the varicella vaccination, almost every child developed chickenpox.¹⁴ Since the introduction of the childhood vaccine in the US in 1995, there has been an 88% decrease in hospitalizations due to chickenpox. It is estimated that \$84.9 million was spent in the US from 1994 to 1995 for varicella hospitalizations and ambulatory visits. In 2002, this decreased by 74% to \$22.1 million. While vaccination decreases the incidence of chickenpox, mathematical models predict an increase in shingles approximately 5 years after vaccine implementation⁷ due to a decrease in cell mediated immunity.

To prevent herpes zoster, boosts in cell-mediated immunity (from either periodic exposure to persons with varicella or routine periodic release of VZV from the ganglia) are necessary.¹⁴ Studies have shown that before the introduction of childhood varicella immunization, adults who lived or worked with children had lower risk of developing herpes zoster than those adults with infrequent exposure to children.¹⁴ With fewer children being exposed to the wild-type varicella virus in the future, this is expected to create an increased incidence of shingles in those under 50 (in this age group, the risk of developing zoster was previously low because of routine boosts in cell-mediated immunity).¹⁴ Similarly, decreased exposure along with a decrease in cell-mediated immunity is expected to increase the incidence of shingles in the elderly.¹⁴ Among the vaccinees, the incidence of zoster is expected to be lower because they may develop a lower degree of ganglion population by the virus (skin lesions develop only in a small number of vaccine recipients).¹⁴

The gradual disappearance of wild-type varicella as more children receive vaccination means that adults will not be receiving routine boosts in cell-mediated immunity from re-exposure to the virus from infected children.¹⁴ The zoster vaccine is meant to substitute for this boosting effect that will not be provided by vaccinated children.¹⁴

IMMUNIZATION

A variety of drugs are available to reduce the severity and duration of herpes zoster and to attempt to manage the associated pain of postherpetic neuralgia.²² However, no medications can prevent disease development or postherpetic neuralgia.²²

Zostavax, a live attenuated virus vaccine for herpes zoster, was approved for the prevention of herpes zoster in the US in 2006 for individuals age 60 and older.²³ Cell-mediated immunity against the varicella zoster virus progressively decreases with age and although the mechanism is still unclear, the VZV vaccine is thought to boost this immunity.^{3,5} The fact that the zoster vaccine is approved only for adults age 60 and over may result in an increase in the incidence of herpes zoster in those under 50 in the next several decades, who, before the development of the childhood varicella vaccination,

would receive periodic re-exposure to wild-type virus to boost their immunity.¹⁴

The purpose of the Shingles Prevention Study was to determine if vaccination with live attenuated VZV vaccine would decrease the incidence and severity of herpes zoster and post herpetic neuralgia in those older than 60.⁵ This randomized, double-blind, placebo-controlled study was conducted in adults age 60 and older. The Shingles Prevention Study found that the vaccine decreased the incidence of both herpes zoster (51.3%) and postherpetic neuralgia (66.5%) in the vaccine group. In those who did develop herpes zoster, the duration and associated pain of herpes zoster was decreased. The vaccine was not found to induce cases of herpes zoster⁵ and adverse events related to the vaccine were limited to the injection site (erythema, pain, tenderness, swelling, or pruritus – all generally mild).⁵

The duration of efficacy for the Zostavax vaccine in the past four years has not yet been determined and it is not yet known whether revaccination will be required.²³

In summary, herpes zoster and its complications can be a debilitating condition. Aggressive early management with antiviral medications will decrease the incidence and severity of postherpetic neuralgia. The advent of the zoster vaccine may help reduce the incidence of ocular complications from HZO. □

Acknowledgement

The authors wish to express their appreciation to Michele Mabon, MD, FRCSC, from the University of Montreal, for providing the clinical photos.

REFERENCES

1. Brisson M, Edmunds WJ, Law B, et al. Epidemiology of varicella zoster virus infection in Canada and the United Kingdom. *Epidemiol Infect* 2001; 127: 305-314.
2. Opstelten W, Zaai MJW. Managing ophthalmic herpes zoster in primary care. *BMJ* 2005; 331: 147-151.
3. Levin MJ, Smith JG, Kaufhold RM, et al. Decline in varicella-zoster virus (VZV)-specific cell-mediated immunity with increasing age and boosting with a high-dose VZV vaccine. *JID* 2003; 188: 1336-1344.
4. Gross G, Schofer H, Wassilew S, et al. Herpes zoster guideline of the German Dermatology Society (DDG). *J Clin Virol* 2003; 26: 277-289.
5. Oxman MN, Levin MJ, Johnson GR, et al. A vaccine to prevent herpes zoster and postherpetic neuralgia in older adults. *N Engl J Med* 2005; 352: 2271-2284.
6. Edgar BL, Galanis E, Kay C, et al. The burden of varicella and zoster in British Columbia 1994-2003: baseline assessment prior to universal vaccination. *Canada Communicable Disease Report* 2007; 33: 1-15.
7. Russell ML, Schopflocher DP, Svenson L, Virani SN. Secular trends in the epidemiology of shingles in Alberta. *Epidemiol Infect* 2007; 135: 908-913.
8. Colin J, Prisant O, Cochener B, et al. Comparison of the efficacy and safety of valacyclovir and acyclovir for the treatment of herpes zoster ophthalmicus. *Ophthalmology* 2000; 107: 1507-1511.

9. Zaal MJW, Völker-Dieben HJ, D'Amaro J. Prognostic value of Hutchinson's sign in acute herpes zoster ophthalmicus. *Graefe's Arch Clin Exp Ophthalmol* 2003; 241: 187-191.
10. Kaufman SC. Anterior segment complications of herpes zoster ophthalmicus. *Ophthalmology* 2008; 115: S24-S32.
11. Kaufman SC. Use of photorefractive keratectomy in a patient with a corneal scar secondary to herpes zoster ophthalmicus. *Ophthalmology* 2008; 115: S33-S34.
12. Pavan-Langston D, Dohman CH. Boston keratoprosthesis treatment of herpes zoster neutrophic keratopathy. *Ophthalmology* 2008; 115: S21-S23.
13. Thean JHJ, Hall AJH, Stawell RJ. Uveitis in herpes zoster ophthalmicus. *Clinical and Experimental Ophthalmology* 2001; 29: 406-410.
14. Liesegang TJ. Herpes zoster ophthalmicus - natural history, risk factors, clinical presentation, and morbidity. *Ophthalmology* 2008; 115: S3-S12.
15. Van der Lelij A, Ooijman FM, Kijlstra A, et al. Anterior uveitis with sectoral atrophy in the absence of keratitis - A distinct clinical entity among herpetic eye diseases. *Ophthalmology* 2000; 107: 1164-1170.
16. Watson CPN, Oaklander AL. Postherpetic neuralgia. *Pain Practice* 2002; 2: 295-307.
17. Tyring SK. Management of herpes zoster and postherpetic neuralgia. *J Am Acad Dermatol* 2007; 57: S136-142.
18. Pavan-Langston D. Herpes zoster - antivirals and pain management. *Ophthalmology* 2008; 115: S13-S20.
19. Beutner KR, Friedman DJ, Forszpaniak C, et al. Valacyclovir compared with acyclovir for improved therapy for herpes-zoster in immunocompetent adults. *Antimicrobial Agents and Chemotherapy* 1995; 39: 1546-1553.
20. Shen M, Lin H, Lee SS, et al. Double-blind, randomized, acyclovir-controlled, parallel-group trial comparing the safety and efficacy of famciclovir and acyclovir in patients with uncomplicated herpes zoster. *J Microbiol Immunol Infect* 2004; 37: 75-81.
21. Tyring S, Engst R, Corriveau C, et al. Famciclovir for ophthalmic zoster: A randomized acyclovir controlled study. *Br J Ophthalmol* 2001; 85: 576-581.
22. Betts RE. Vaccination strategies for the prevention of herpes zoster and postherpetic neuralgia. *J Am Acad Dermatol* 2007; 57: S143-147.
23. Merck & Co., ed. Highlights of prescribing information – Zostavax Zoster Vaccine Live; 2006.