

Refractive Surgical Problem

Edited by Sonia H. Yoo, MD

A 32-year-old man planned to have laser in situ keratomileusis (LASIK) in both eyes. The preoperative manifest refraction was $-6.50 + 1.00 \times 80$ in the right eye and $-6.25 + 1.00 \times 90$ in the left eye, yielding a visual acuity of 20/20 in both eyes. Topography was normal. Ultrasound pachymetry was $581 \mu\text{m}$ in the right eye and $574 \mu\text{m}$ in the left eye.

The LASIK procedure was performed with a femtosecond laser, creating an 8.8 mm, $110 \mu\text{m}$ flap without incident in the right eye. In the left eye, however, a dense opaque bubble layer (OBL) appeared to interfere with the laser dissection. When a flap lift was attempted, the flap adhered to the underlying stromal bed. Therefore, the LASIK was aborted in the left eye.

Postoperatively, the uncorrected distance visual acuity (UDVA) was 20/20 in the right eye. There was no change in refraction or topography in the left eye. **Figure 1** shows a slitlamp photograph of the left eye.

Would you advise this patient to have the left eye treated and if so, when? What procedure(s) would you consider for the patient? If you elect to perform LASIK in the left eye, what would the flap parameters be; would you choose a microkeratome or femtosecond laser to create the flap?

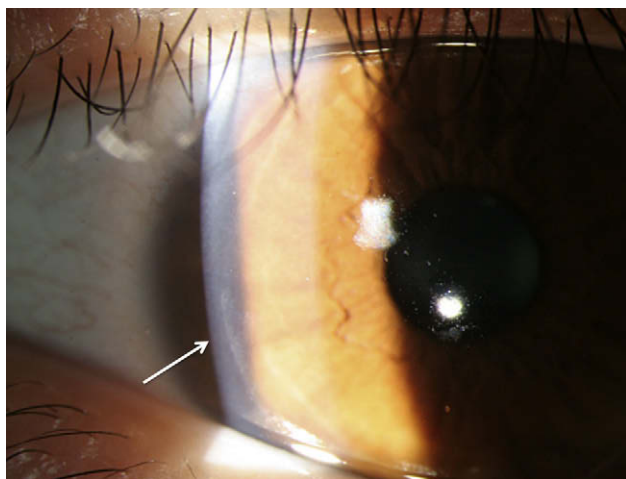


Figure 1. Slitlamp photograph after aborted LASIK in the left eye. Note the resolution of the OBL and edge of the side cut (arrow).

■ In this case, successful femtosecond LASIK was performed in the right eye while the procedure had to be aborted in the left eye. From the information provided, there were no risk factors present and the patient was a good surgical candidate. I see no contraindication to proceeding with surgery in the left eye. The question is when and what type of surgery.

The right eye had an excellent outcome, and after the aborted surgery, the left eye returned to presurgical parameters. The surgeon exercised good clinical judgment by not forcing a flap lift under the circumstances. Aborted femtosecond laser procedures can occur due to loss of suction during lamellar dissection or during creation of the side cut. Also, a dense OBL could interfere with the laser dissection, subsequent flap lift, iris recognition, or laser tracking. Most often, the OBL is seen after the laser dissection has been completed in a certain area. At times, OBL formation can be rapid and extend to the leading edge of the dissection, as it presumably did in this case. In this situation, one can only assume that the lamellar dissection would not have been properly completed. It is important that there was no problem in the creation of the side cut in its entirety, as shown by the typical healing pattern in **Figure 1**.

Retreatment could be done on the same day or later. I would favor treating at a later date. Some would argue that by waiting 20 to 30 minutes for the OBL to dissipate, one could attempt a flap lift on the same day. However, the surgeon concluded that a proper dissection had not been completed. A new femtosecond laser dissection could be attempted following the loss-of-suction protocol. In this approach, when suction is lost during the flap creation, the suction ring is replaced on the eye and the dissection repeated and completed with excellent results, in the same sitting. In the clinical scenario at hand, I would favor a more conservative approach that would involve postponing surgery for at least 2 weeks. Good outcomes are possible after aborted LASIK flaps.¹

I would consider 2 possible procedures for this patient: (1) LASIK and (2) photorefractive keratectomy (PRK) with mitomycin-C (MMC) 0.02%. Had a microkeratome been used and a buttonhole or incomplete flap occurred,² I would have proceeded with PRK using MMC for 12 seconds, followed by copious irrigation. However, as this procedure was originally

performed using the femtosecond laser and no evidence of central irregularities or opacities exist in Figure 1, I would proceed with femtosecond LASIK. Assuming that the side cut created in the left eye would be the same size as the cut in the right eye (ie, 8.8 mm), my parameters would be simply a 105 μm lamellar dissection that is 9.0 mm in diameter to achieve some overlap of the dissections. I would try to use the already-created 8.8 mm side cut to preserve the integrity of the wound as much as possible.

Guillermo Rocha, MD, FRCSC
Brandon, Manitoba, Canada

REFERENCES

1. Jabbur NS, Myrowitz E, Wexler JL, O'Brien TP. Outcome of second surgery in LASIK cases aborted due to flap complications. *J Cataract Refract Surg* 2004; 30:993–999
2. Al-Mezaine HS, Al-Amor SA, Al-Obeidan S. Incidence, management, and visual outcomes of buttonholed laser in situ keratomileusis flaps. *J Cataract Refract Surg* 2009; 35:839–845

■ This patient has no red flags; therefore, I would recommend a reattempt of LASIK with a customized flap in the left eye.

Photorefractive keratectomy would not be the best option because of the risk for haze associated with high myopic correction. In addition, when PRK is performed over LASIK flaps and for this amount of correction, ablation to the old stromal bed can occur, resulting in tissue slivers and irregular astigmatism.

To retreat this patient, I would wait at least 3 months to ensure better stability of the primary flap. Healing across the flap–stromal bed interface is weak, as is seen when LASIK flaps are lifted several years after the primary surgery. However, better healing occurs at the side-cut wounds, and in vivo confocal microscopy has shown healing to be complete by 3 to 6 months.¹

To customize the second flap, the primary flap must be precisely mapped. A very-high-frequency digital ultrasound scan or high-definition corneal OCT would provide more reliable data than the parameters targeted for the primary cut.

Thus, there are 3 options. The first is to create a flap with the same parameters as the primary flap. Possible differences in applanation pressure, hydration conditions, or conjunctival chemosis can result in a different level cut. This can lead to 2 intersecting stromal cuts with irregular bed or tissue slivers. The second option is to create a thinner and smaller diameter flap inside the primary flap. This is not advisable for the same reason that PRK is not the best option. In addition,

manipulation of the superficial flap can cause striae of the primary flap. I would recommend the third option, which is to aim for a thicker and larger diameter flap, especially given that the patient's cornea is thick enough to allow a deeper cut. This flap will contain and isolate the old flap and will have more stability with less risk for complications.

I would use a femtosecond laser rather than a mechanical microkeratome to create the flap. With a microkeratome, there is lower predictability and the cut is varied from the periphery to the center, which would complicate accurately planning of the second cut. In contrast, the improved predictability of flap diameter, thickness, and uniformity with the femtosecond laser make it a better choice for recutting procedures. The drawback of using a femtosecond laser to recut this cornea is the risk for bubble breakthrough to the old side cuts; however, if this were to happen, it would be in the periphery away from the ablation zone.

Regarding flap parameters, there must be a separation of at least 30 μm (50 μm if using a no-pocket flap pattern) between the old dissection plane and the new dissection plane to ensure that a gas bubble does not spread to the old primary interface and intersection of the 2 interfaces.²

Finally, despite being unlikely, the risk for formation of an OBL dense enough to interfere with the treatment cannot be eliminated. To decrease the risk, the surgeon might try to adjust the pocket parameters, use a higher frequency femtosecond machine, or apply lighter applanation, especially near the hinge.

Mohamed Abou Shousha, MD
Miami, Florida, USA

REFERENCES

1. Vesaluoma MH, Petroll WM, Pérez-Santonja JJ, Valle TU, Alió JL, Tervo TM. Laser in situ keratomileusis flap margin: wound healing and complications imaged by in vivo confocal microscopy. *Am J Ophthalmol* 2000; 130:564–753
2. Tran DB, Binder PS, Brame CL. LASIK flap revision using the IntraLase femtosecond laser. *Int Ophthalmol Clin* 2008; 48:51–63

■ This 32-year-old patient with mild myopia and astigmatism has excellent corrected distance visual acuity in both eyes. Ultrasound pachymetric measurements show that it would be safe to perform LASIK with the femtosecond laser, which is the best option to correct this patient's refractive problem. The patient had successful LASIK in the right eye with an early postoperative UDVA of 20/20. In the left eye, the LASIK procedure was postponed due to suction loss